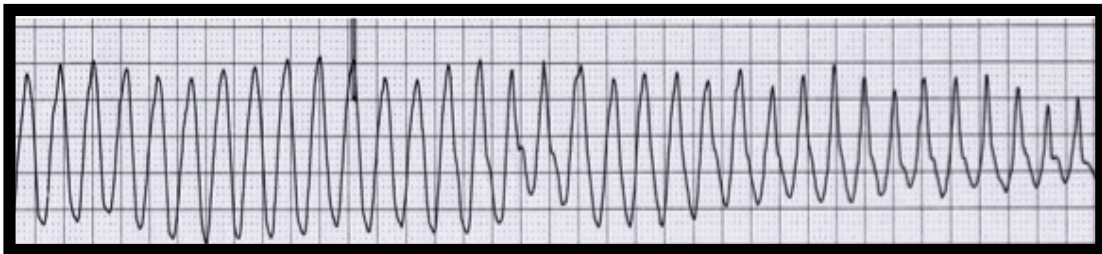


Wide-Complex Tachycardias in the ED: Myths and Pitfalls



Amal Mattu, MD, FACEP, FAAEM
Professor and Vice Chair
Director, Emergency Cardiology Fellowship
Department of Emergency Medicine
University of Maryland School of Medicine
Baltimore, Maryland

OBJECTIVES

At the conclusion of this presentation, each participant should be able to. . .

1. Identify difficulties in distinguishing amongst various types of wide complex tachycardias.
2. Describe pitfalls in the diagnosis and treatment of WPW-related tachydysrhythmias.
3. List the shortcomings associated with the use of amiodarone in managing patients with wide complex tachycardias.

I. ECG Diagnosis of Wide Complex Tachycardias

ACLS 2000 — Stable WCT, unknown type: “Attempt to establish a specific diagnosis”

- 12-lead ECG
- Esophageal lead
- Clinical information

Myth: The electrocardiogram can reliably distinguish between VT and SVT-AC.

Classic teaching: “...assume WCT is VT *until proven otherwise*...”
“...*when in doubt*, assume and treat WCT as VT...”

ECG clues favoring VT:

AV dissociation	QRS > 140 ms. or RS > 100 ms.
Captured beats	Precordial concordance
Fusion beats	V1: taller left “rabbit ear”
Leftward axis	V1: “steeple sign
Rightward axis	V6: rS, QS, or QR complex
Extreme rightward axis	V6: S or QS > 15 mm deep

Brugada Criteria (*Circulation*, 1991)

1. Absence of RS complex in all precordial leads?
 2. RS interval > 100 ms. in one precordial lead?
 3. AV dissociation?
 4. Morphology criteria for VT present in precordial leads V₁₋₂ and V₆?
- Sensitivity 98.7%, specificity 96.5%

Herbert, et al (*Ann Emerg Med*, 1996)

- 27 ECGs with WCT from ED records
- Three emergency physicians
- Apply Brugada criteria
- 22% disagreement in distinguishing VT from SVT-AC

Isenhour, et al (*Acad Emerg Med*, 2000)

- 157 ECGs with WCT, final diagnosis confirmed electrophysiologically
- Two cardiologists, two emergency physicians
- Apply Brugada criteria
- Sensitivity at diagnosing VT
 - Emergency physicians: 83% and 79% (interobserver agreement 82%)
 - Cardiologist: 85% and 91% (interobserver agreement 81%)

Jastrzebski, et al. (*Europace*, 2013)

- 260 WCTs of which 159 were VT
- Sensitivities for detecting VT...

- Brugada 89%
- Griffith 94%
- Bayesian 89%
- Vereckeï aVR 87%
- Lead II RWPT 60%

Szelenyi, et al. (*Acad Emerg Med*, 2013)

- 212 WCTs of which 142 were VT
- Sensitivities for detecting VT
 - Vereckeï 92%
 - Lead II RWPT 79%

Pitfall: assumption of SVT-AC based on “clinical information” (hemodynamic status, young age, absence of history of CAD, etc.)

II. Adenosine

Myth: Adenosine can reliably distinguish between VT and SVT-AC.

Reality:

1. Adenosine will not convert all patients with SVT-AC.
2. Adenosine *will* convert some patients with VT!

Adenosine-sensitive VT

- Well-documented in the adult cardiology (EP) literature
- Often are young patients with no known underlying cardiac disease
 - Hina, et al (*Jpn Heart J*, 1996)
 - Terminated VT in 5 out of 10 adult patients
- Documented in pediatric patients as well
 - Lenk, et al (*Acta Paediatr Jpn*, 1997)
 - Terminated VT in 5 out of 8 pediatric patients

III. Wolff-Parkinson-White Syndrome

- Orthodromic SVT
 - Narrow-complex regular tachycardia
 - Looks like any other SVT
 - Can treat like any other SVT
 - Adenosine and other AV nodal blockers generally considered safe
- Antidromic SVT
 - Wide-complex regular tachycardia
 - Looks like VT; very difficult to distinguish
 - Safety of adenosine and other AV nodal blockers *probably* safe
 - Beware adenosine-induced atrial fibrillation (increased susceptibility?)

- Cardioversion, procainamide, and amiodarone effective
- Atrial fibrillation
 - Very rapid irregularly irregular tachycardia (rates may approach 300 beats/min.)
 - Often misdiagnosed as SVT, VT, or atrial fibrillation with BBB

Pitfall: Treatment of WPW + atrial fibrillation with AV nodal blockers

- Adenosine and other AV nodal blockers may be deadly!
 - *Avoid amiodarone*
- Cardioversion and procainamide effective

IV. Treatment of Ventricular Tachycardia

Pulseless VT — defibrillate (unsynchronized) 200J, etc.

Unstable VT with pulse — cardiovert (synchronized) 100J, etc.

Stable VT — lidocaine was considered the treatment of choice

Myth: Lidocaine is a very effective treatment for patients in stable VT.

Reality: Lidocaine has a very poor success rate (~20-30%) for conversion of stable VT to NSR.

Armengol, et al (*Ann Emerg Med*, 1989) — Conversion rates of lidocaine for stable VT

- 17 consecutive patients with stable VT treated with up to three boluses of lidocaine
- Overall success rate 5/17 (29%)

Ho, et al (*Lancet*, 1994) — Sotalol vs. lidocaine for stable VT

- 33 patients randomized (double blind) to receive either 100 mg sotalol or 100 mg lidocaine
- 11/16 (69%) converted with sotalol
- 3/17 (18%) converted with lidocaine
 - Crossover trials for initial failures
 - Sotalol successful in 18/30 (60%) patients overall
 - Lidocaine successful in 4/22 (18%) patients overall

Gorgels, et al (*Am J Cardiol*, 1996) — Procainamide vs. lidocaine for stable VT

- 29 patients randomized to receive either procainamide 10 mg/kg at 100mg/min vs. lidocaine 1.5 mg/kg over 2 minutes
- Procainamide successful in 12/15 patients (80%)
- Lidocaine successful in 3/14 patients (21%)
- Crossover trials for initial failures
 - Procainamide successful in 20/26 patients (77%)
 - Lidocaine successful in 4/15 patients (27%)

Marill, et al (*Acad Emerg Med*, 1997) — Conversion rates of lidocaine for stable VT

- Single bolus successful in 6/35 patients

- Second bolus successful in 4/22 patients
- Overall success rate 10/35 (29%)
- Electrical cardioversion successful in 16/18 cases (average dose 89J)

Procainamide — excellent success rates for all types of WCT

- Ventricular tachycardia
- SVT or atrial fibrillation with BBB
- SVT or atrial fibrillation with WPW

Procainamide drawbacks

- Hypotension
- Prolongation of QRS and/or QT intervals
 - Avoid in TdP and TCA overdose
- Slower onset of action than lidocaine and amiodarone
- Side effects are all reversible
- Cardiovert unstable patients
- Currently listed as DOC for stable monomorphic VT with normal EF (??)

Ventricular tachycardia — other drugs

- Bretylium
 - Significant incidence of vomiting, prolonged hypotension
 - Production discontinued, removed from ACLS algorithms
- Magnesium
 - May be effective in refractory stable VT (Allen, *Am J Cardiol*, 1989)
 - Bolus and *continuous infusion*
- Amiodarone
 - Had become the DOC for stable VT, but on further review...
 - Marill, et al (*Ann Emerg Med*, 2006) — Conversion rates of amiodarone for stable VT only 29%
 - Cummins, et al (*Ann Emerg Med*, 2006) — most prior studies only indicated success rate 40-60%
 - Tomlinson, et al (*Emerg Med J*, 2008) — Conversion rates of amiodarone for stable VT only 29%
 - Only 15% success rate within 20 minutes
 - ACC/AHA/ESC 2006 Guidelines for Management of Patients With Ventricular Arrhythmias and Prevention of Sudden Cardiac Death — Executive Summary, *Circulation*, Sept. 5, 2006
 - “Intravenous amiodarone is not ideal for early conversion of stable monomorphic VT. Intravenous procainamide is more appropriate when early slowing of the VT rate and termination of monomorphic VT are desired.”
 - “IV amiodarone is reasonable for patients with sustained monomorphic VT that is hemodynamically unstable, refractory to conversion with countershock, or recurrent despite procainamide or other agents.”

- AHA 2010 Guidelines for ACLS
 - Procainamide Class IIa, amiodarone now Class IIb
- May cause hypotension (less often than procainamide), bradycardia, prolongation of QT interval
- Overall summary of amiodarone
 - Dangerous in the setting of prolonged QT, pregnancy (Class D → may cause fetal hypothyroidism), rapid atrial fibrillation + WPW, AIVR and other “slow VT” conditions
 - Not as effective as we had believed for stable VT
 - Ineffective for VF (see below)

V. Summary

- Assume *all* regular WCTs are VT.
- Response of a WCT to adenosine does not rule out VT.
- Look carefully for irregularity in WCTs (potential for atrial fibrillation with WPW); avoid adenosine and other AV nodal blockers!
- Amiodarone is not a cure-all for ventricular arrhythmias
 - Dangerous in the setting of prolonged QT, pregnancy, rapid atrial fibrillation + WPW, AIVR and other “slow VT” conditions
 - Not as effective as we had believed for stable VT.
- Procainamide should be considered the DOC for stable VT
 - Caveats
 - Avoid in torsades and type IA-type drug toxicities (prolongation of QT interval).
 - When in doubt, cardiovert!

Questions or comments? Please contact me:

Amal Mattu, MD

amalmattu@comcast.net